

# PROGRESSIVE STRIPPING THERAPY BY DR. ECHARRI

**Stripping** is a mechanical removal of a part of proximal enamel layer of the teeth, with an objective to remodel the shape and the position of the interproximal contact area and to reduce mesio-distal diameter of the teeth in order to carry out the re-approximation, alignment, and correction of rotations, as well as to compensate Bolton discrepancies.

## Objectives of stripping

- To correct alterations of dento-alveolar discrepancy.
- To correct alterations of upper and lower teeth size discrepancy (Bolton discrepancy).
- To adapt interdental contact point to the papilla shape.
- To increase the interdental contact point surface which provides more stability to corrected rotations.
- To set up the occlusion so that dental cusps of an arch fit to interdental spaces and slots of the antagonist teeth.
- To correct the dental asymmetry for esthetic improvement.
- To center the midline.

## Indications for stripping

- Mild negative dento-alveolar discrepancies.
- Bolton discrepancies.
- Triangular tooth shape.
- Macrodonia.
- Over-sized crowns and fillings.
- Bilateral dental asymmetries.
- Adult patient (retracted pulp).
- Low caries index.
- Good hygiene (low bacterial plaque index).
- Multiple rotations because of stability.
- Special cases:
  - Temporary molars with agenesis of bicuspids to adjust the occlusion.
  - Lower stripping to adjust upper incisors affected by microdonia.
  - Upper stripping in a lower incisor extraction cases.
- Patient who accepts stripping (with previous warning).

## Counter indications of stripping

- Patient who doesn't accept stripping.
- High caries index.
- Poor hygiene. High bacterial plaque index.
- Square tooth shape.
- Young patient (big pulp chamber).
- Patient with hyper sensibility.
- Patients with imperfect histogenesis.
- Teeth with abraded proximal surfaces.
- It cannot be used to correct molar Class II and II mal occlusions.

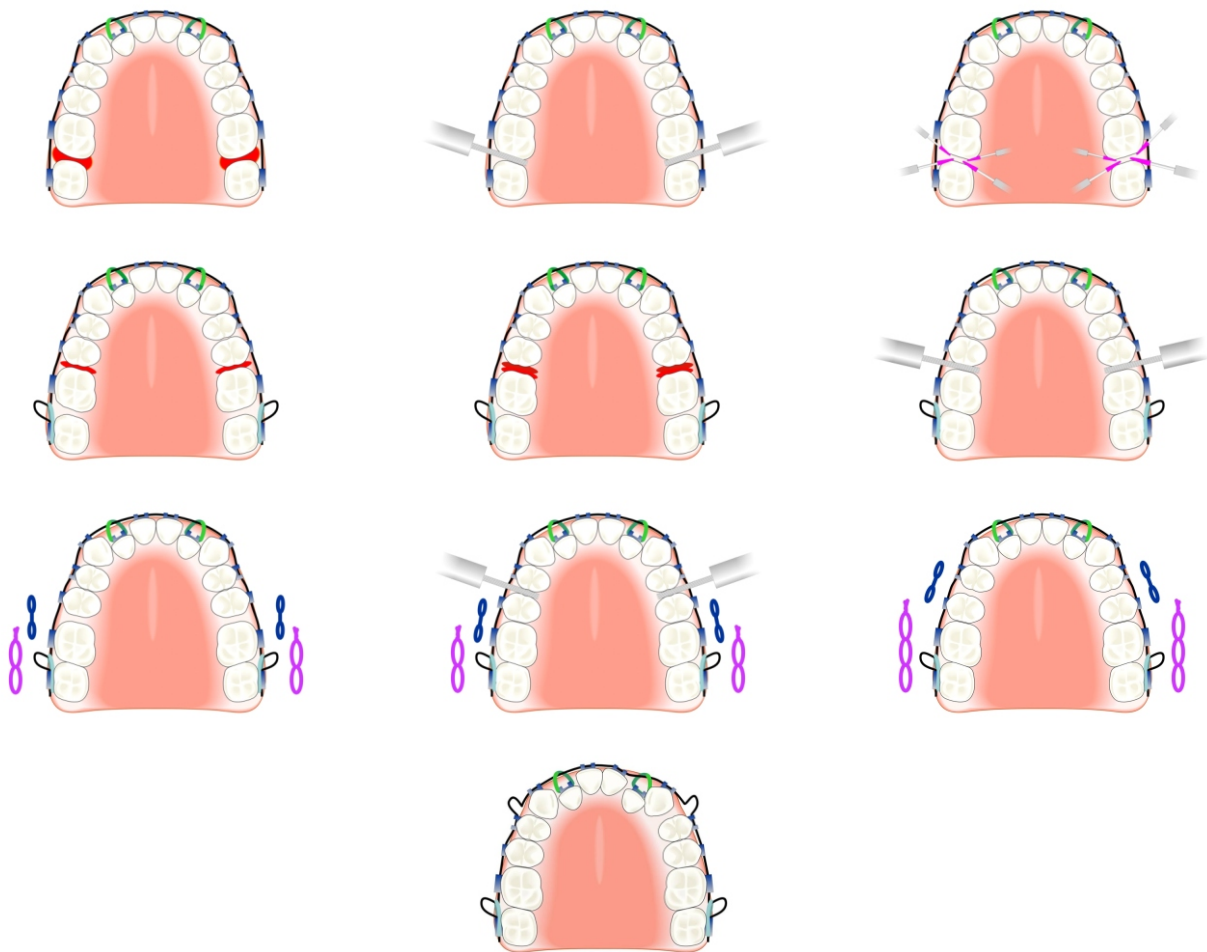
## Advantages of stripping

- Stripping minimizes the extraction indications and its consequences:
  - Difficulties in space closure due to side effects of arch wires.
  - Difficulties in parallelizing the roots of neighboring teeth after extraction.
  - Extraction cases require more reinforcement of anchorage, although the anchorage control is also fundamental in stripping cases.
  - Relapse possibility due to reopening of extraction spaces.
- Less dental material loss.
- Less amplitude of dental movements.
- Shorter treatment time.
- Less risk of root resorption (due to less amplitude of movement and due to shorter treatment time).
- Better stability (especially in rotations).
- Better esthetics:
  - The asymmetries in anterior sector can be compensated and it can help in midline centering.
  - In posterior group, it can help to fit the cusps in the antagonist grooves to improve the intercuspation.
  - Vertical stripping can help to align the vertex of papillae with contact points.
  - Eliminates "black triangles".

## Progressive Stripping Technique

Progressive Stripping Technique is carried out:

- Without anesthesia.
- With irrigation.
- With appropriate burs.
- Without protection of soft tissues.
- Tooth by tooth, starting from the most distal tooth.
- With previous separation.
- Polishing until smooth surface is achieved.
- Before alignment.
- With fluor application after stripping.
- If the stripping is indicated on both sides or in both arches, then it is done simultaneously.



Depending on the Bolton index, the progressive stripping technique can be:

- Total.
- Anterior.
- Posterior.

## The frequency of appointments

- The lapse between 1<sup>st</sup> and 2<sup>nd</sup> appointment (separation 6-7) can be some 3-7 days.
- To complete ALR, the appointments must be at each 15 days.
- After ALR has been finished, the appointments should be at each 4-5 weeks.

## Progressive Stripping Technique: Advantages

- "Round-treatment" is not carried out.
- Good anchorage control is kept.
- Soft tissues are protected (gums, tongue, lips).
- Labial and lingual surfaces of the teeth are protected, and only the contact point can be trimmed, through the access provided by the separation.
- Smoothing process of the trimmed zone can be controlled with a probe and dental floss, and fluor can be applied without any problems.
- It can be checked if the cusps fit well in intercuspation, and a midline can be controlled.
- The distance from the contact point to the bone crest can be measured without any problems.
- The verticality between the contact point and interdental papilla can be controlled.

## Arch wire sequence

- .016" SS with omegas during the stripping.
- .016" NiTi.
- .016" x .022" NiTi or SS with omegas.
- .018" x.025" SS with omegas.

## How much enamel can be trimmed?

	Central incisor		Lateral incisor		Canine		First bicuspid		Second bicuspid		First molar	
	mesial	distal	mesial	distal	mesial	distal	mesial	distal	mesial	distal	mesial	
Upper jaw	0.5	0.5	0.3	0.3	0.5	0.5	0.5	0.5	0.5	0.5	0.5	
<b>Interdental reduction</b>	1.0	0.8		0.8		1.0		1.0		1.0		
Lower jaw	0.3	0.3	0.3	0.3	0.5	0.5	0.5	0.5	0.5	0.5	0.5	
<b>Interdental reduction</b>	0.6	0.6		0.8		1.0		1.0		1.0		

IER (Interdental Enamel Reduction) Chart.

It can be trimmed:

- 0.5 mm on mesial and distal surface of upper central incisors, upper and lower canines, upper and lower bicuspid, and upper and lower molars.
- 0.3 mm on mesial and distal surface of upper lateral incisors, and four lower incisors.

## How long enamel can be trimmed?

To trim 0.5 mm, it should be used:

- 60 µm file for 60 seconds.
- 25 µm file for 30 seconds.
- 15 µm file for 30 seconds.

To trim 0.3 mm, it should be used:

- 40 µm file for 30 seconds.
- 25 µm file for 30 seconds.
- 15 µm file for 30 seconds.

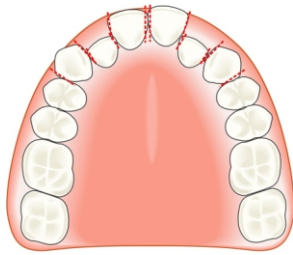
## Stripping and CA Clear Aligner

In other aligners techniques, first the stripping plan is computer-designed, or laboratory-designed, and then the orthodontist should reproduce it in the patient's mouth.

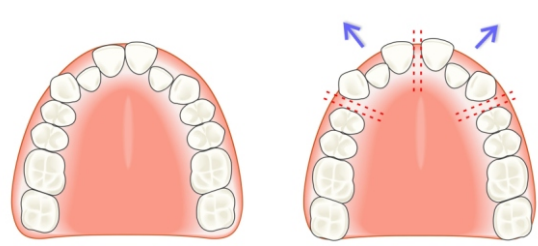
As Clear Aligner technique is based on the fact that the new impressions are taken at each appointment, first the stripping is carried out in the patient's mouth, and then the impressions are taken.

Clear Aligner combined with Dr. Echarri's Progressive Stripping Technique is carried out in the following way (Fig. 1):

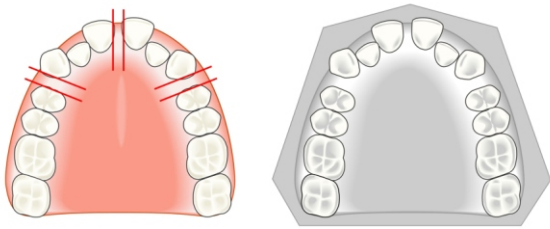
1. Clear Aligner is used to carry out oblique-lateral expansion and to open the spaces (Fig. 2):
  - a. Between canines and the first bicuspid.
  - b. Between two central incisors.
2. The stripping is carried out in (Fig. 3):
  - a. Distal surface of canines.
  - b. Mesial surface of the first bicuspid.
  - c. Mesial surface of central incisors.
3. New impressions are taken and the previous Clear Aligner is kept (Fig. 3).
4. Canines are moved distally and central incisors are moved mesially until the space is opened on mesial and distal side of lateral incisors (Fig. 4).
5. Stripping is carried out in (Fig. 5):
  - a. Distal surface of central incisors.
  - b. Mesial and distal surface of lateral incisors.
  - C. Mesial surface of canines.
6. New impressions are taken and the previous Clear Aligner is kept (Fig. 5).
7. Alignment is finished (Fig. 6).



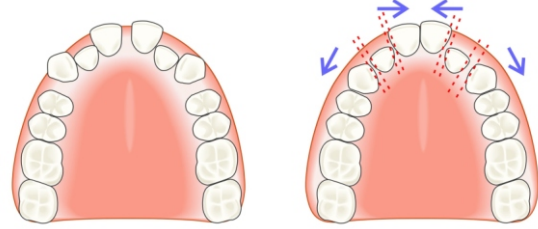
1. Canine-to-canine stripping scheme.



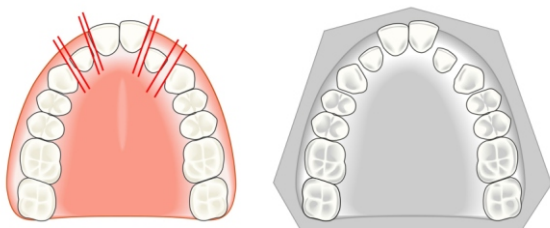
2. Use of Clear Aligner in oblique-lateral expansion and space opening: between canines and the first bicuspids, and between the central incisors.



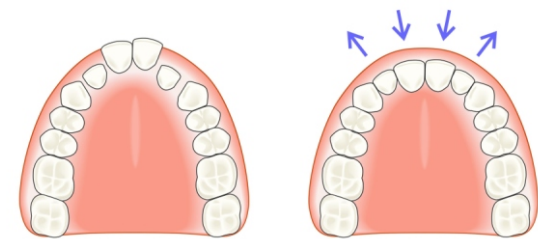
3. Stripping of distal surface of canines, the mesial surface of the first bicuspids, and the mesial surface of central incisors. New impressions are taken and the previous Clear Aligner is kept.



4. Canines are moved distally, and central incisors are moved mesially, until the spaces are opened on the mesial and distal sides of lateral incisors.



5. Stripping of distal surface of central incisors, mesial and distal surfaces of lateral incisors, and the mesial surface of canines. New impressions are taken, and the previous Clear Aligner is kept.



6. Finish the alignment.